

Metaplastic Carcinoma Breast: A Clinical Analysis of Nine Cases

MANASHI GHOSH¹, A MUNEEER², VINITA TRIVEDI³, KAUSTAV MANDAL⁴, SANTOSH SHUBHAM⁵

ABSTRACT

Metaplastic Breast Carcinoma (MBC) is a rare heterogeneous group of primary breast malignancies with different subgroups; exhibits a variety of histopathologic patterns and appears to be both epithelial and mesenchymal in origin. The ideal treatment for MBC remains unknown, due to its low incidence and pathological variability. Owing to its rarity, MBC has been treated as a variant of Invasive Duct Carcinoma (IDC). But it has poorer prognosis as compared to IDC. This is a case series to evaluate clinicopathologic characteristics and the multi-disciplinary treatment of nine MBC patients treated in a single institute.

Keywords: Adjuvant radiotherapy, Cancer, Metaplasia, Poor prognosis, Rare disease

MBC is a rare histological subtype of carcinoma breast. It is classified into low-grade adenosquamous carcinoma, fibromatosis-like metaplastic carcinoma, squamous cell carcinoma, spindle cell carcinoma, metaplastic carcinoma with mesenchymal differentiation, mixed metaplastic carcinoma, and myoepithelial carcinoma according to the World Health Organisation (WHO) classification of breast tumour 2012. Optimal treatment of MBC remains controversial. So generally cases of MBC's are managed in the same way as like IDC. Standard treatment comprises surgery followed by adjuvant chemoradiotherapy. Even though MBC are treated in the same way as IDC; it differs in several pathological and clinical aspects. The prognosis and optimal treatment for MBC are largely not well studied. Also, not many authors have attempted to delineate the factors that make MBC different from more common malignant breast cancer.

CASE SERIES

A total of nine patients were diagnosed as MBC at Department of Radiation Oncology, Mahavir Cancer Sansthan, Patna, Bihar from July 2015 to January 2017. Retrospective analysis of the demographic data, clinical and pathologic characteristics, treatment, and follow up details of these patients were done in accordance with the predesigned performa [Table/Fig-1].

Median age of nine patients at diagnosis was 50 years (range 19-65 years). The median tumour size at diagnosis was 5.5 cm (range

4-20 cm). None of these patients had distant metastasis at the time of presentation. The median number of positive node was four (range 1-10).

Histological subtypes [Table/Fig-2a-g] were squamous differentiation (56%), carcinosarcoma (22%), adenosquamous (11%), and carcinoma with chondroid differentiation (11%).

Out of nine patients, seven patients had triple negative tumours. Six patients (66%) received three cycles of neoadjuvant chemotherapy with CAF (Cyclophosphamide, Anthracycline and 5-Fluorouracil) regimen, three patients underwent upfront surgery. Two patients underwent breast conservation surgery while seven patients underwent modified radical mastectomy.

Six patients received adjuvant chemotherapy, the drugs used were cyclophosphamide, adriamycin, fluorouracil and paclitaxel. Three patients could not receive adjuvant chemotherapy because of associated co-morbidities.

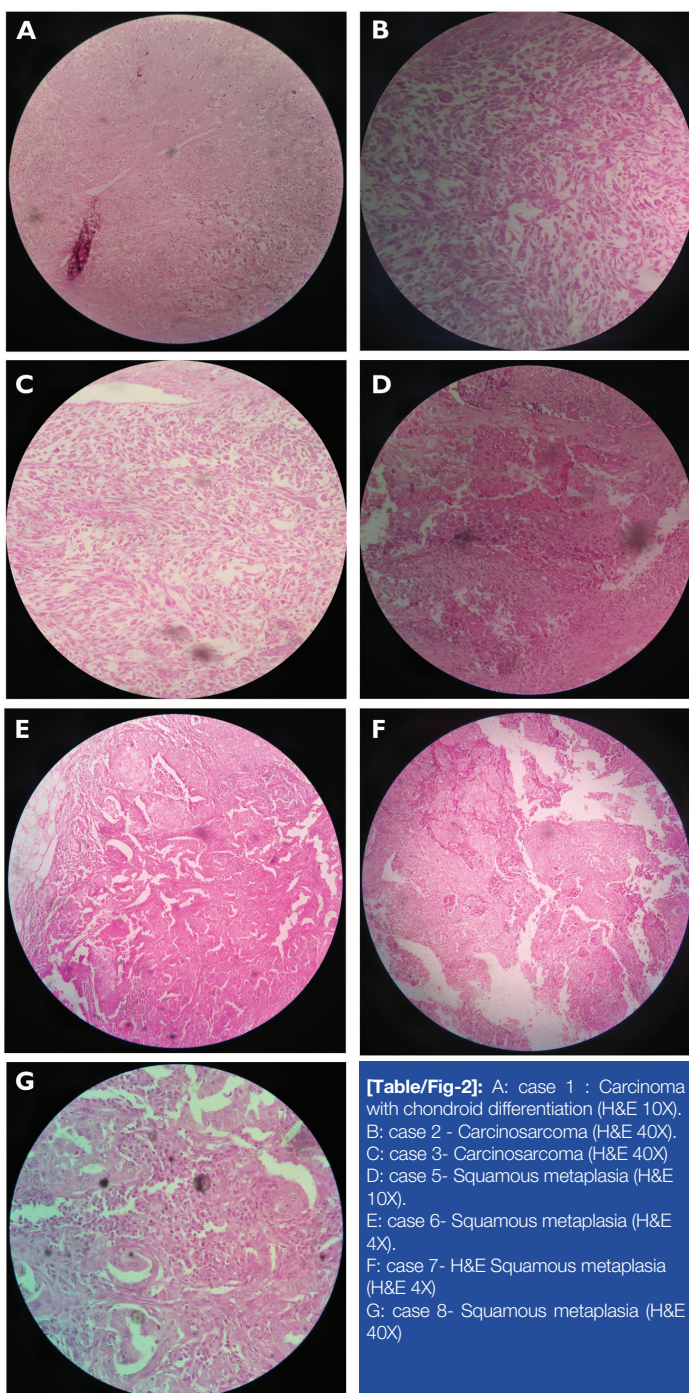
Five patients received postoperative radiotherapy to the chest-wall using cobalt-60 gamma rays with bilateral tangential fields. Total dose of 50 Gray in 25 fractions over five weeks was given. Two (22%) patients developed brain metastasis postoperatively within two-three months. At present two of our patients are due for radiotherapy.

Median follow up was 12 months (range 3.7-16.4 months). At the time of this analysis six patients were alive with no evidence of disease

No	Age	meno-pausal status	Clinical presentation	Tm size (cm)	TNM stage	Pathology	ER	PR	HER2	NACT	Surgery	A-CT	A-RT	Recurrence	Final status	Follow-up (months)
1	55	Post	Pain, Lump	4	IIB	CCM	Negative	positive	Positive	NA	BCS	NA	NA	DM	died	3.7
2	55	Post	Ulcer	20	IIIB	CS	Negative	Negative	Negative	NA	MRM	3CAF,3 P	NA	No	alive	9
3	19	pre	Ulcer	7	IIIB	CS	Positive	Positive	Negative	CAF	MRM	1 CAF, 4 P	50Gy/25#	No	alive	16.4
4	35	pre	Lump	6	IIIB	AS	Negative	Negative	Negative	CAF	MRM	NA	NA	DM	died	5.8
5	42	pre	Lump	3.5	IA	S	Negative	Negative	Negative	NA	BCS	4 CAF 4 P	50Gy/25#	No	alive	12
6	50	Post	Lump	4	IIIB	S	Negative	Negative	Negative	CAF	MRM	CAF	50Gy/25#	No	alive	16.4
7	62	Post	Lump	5.5	IIIB	S	Negative	Negative	Negative	CAF	MRM	1CAF,4 P	50Gy/25#	DM	alive	14.5
8	30	pre	Lump	4	IIIA	S	Negative	Negative	Negative	CAF	MRM	1CAF,4 P	50Gy/25#	No	alive	13.4
9	65	Post	Lump	11	IIIB	S	Negative	Negative	Negative	CAF	MRM	NA	NA	No	alive	7.4

[Table/Fig-1]: Patients' clinical and tumour characteristics.

*Abbreviation: Tm= Tumour, Post=Post-menopausal, Pre= Premenopausal, CCM= Carcinoma with chondroid differentiation, CS=Carcinosarcoma, AS= Adenosquamous, S=Squamous, ER= Estrogen Receptor, PR=Progesterone Receptor, HER2= Human Epidermal Growth factor 2, BCS=Breast Conservation Surgery, MRM=Modified Radical Mastectomy, CAF=Cyclophosphamide, Anthracycline, 5-Fluorouracil, P= Paclitaxel, DM= Distant Metastasis, A-CT Adjuvant chemotherapy, NACT= neoadjuvant chemotherapy, A-RT= Adjuvant radiotherapy.



and one patient was alive with distant metastasis, two patients died of distant metastasis. Most common distant metastatic sites were brain and bone (two patients had brain metastasis, one patient had both brain and bone metastasis).

Whole brain radiotherapy had been started for the patients with brain metastasis but they defaulted for treatment in between and later both of them died. One patient who had developed bone metastasis was given palliative radiotherapy to the bone but one month after radiotherapy she developed brain metastasis also, so whole brain radiotherapy was done and now she is alive.

DISCUSSION

Metaplastic breast carcinomas account for 0.2–5% of all invasive breast cancers [1]. It is characterized by differentiation of the neoplastic epithelium into squamous cells, mesenchymal-looking elements, including but not restricted to spindle, chondroid, osseous, and rhabdomyoid cells. These neoplasms may be either entirely composed of metaplastic elements, or a complex mixture of carcinoma with metaplastic areas [1]. The gross examination of metaplastic carcinomas shows an indistinct or irregular or well-

circumscribed border [2].

Patients with MBC usually present with larger size, higher grade, higher stage and more hormone receptor-negative tumours with less involvement of regional lymph nodes and higher likelihood of distant metastasis as compared to patients with IDCs [3].

Median age of MBC at diagnosis is reported to be around 60 years of age in the literature [4,5]. However, some studies reported much younger age of presentation similar to ours, in which median age was found to be 50 years [6].

Clinical features of metaplastic carcinoma are similar to that of IDC but generally present with a larger tumour size (≥ 5 cm) than IDC [7]. In our series median tumour size was 5.5 cm.

In MBC, lymphatic spread is uncommon. It has been reported that lymph node metastasis only occurs in pure epithelial MBCs [5,8]. The incidence of nodal spread has been reported to be between 0% and 63% [5,6]. In our series, seven patients (78%) had axillary lymph node metastasis. Five out of seven patients with lymph node metastasis had pure epithelial component other two patients had carcinosarcoma, metaplastic carcinoma with mesenchymal differentiation subtype respectively. In general, it has been believed that lymph node metastasis is not a prognostic factor for survival. However, Chao TC et al., showed that axillary lymph node metastasis was associated with worse survival [9].

MBC is a heterogeneous disease with different subgroups. This includes low-grade adenosquamous carcinoma, fibromatosis-like metaplastic carcinoma, squamous cell carcinoma, Spindle cell carcinoma, metaplastic carcinoma with mesenchymal differentiation, mixed metaplastic carcinoma, and myoepithelial carcinoma. In our series, squamous cell carcinoma was the most common histopathological subtype (five out of nine patients). Two patients had sarcomatous differentiation and one patient had metaplasia with chondroid differentiation subtype. MBC with sarcomatous differentiation is associated with poor prognosis [10].

Due to rarity, there are no specific guidelines for the management of MBC. Surgery is the main curative approach for MBC. Mastectomy or breast conservation surgery is most commonly performed [11]. Axilla is generally managed by axillary lymph node dissection [12]. In our series, two patients underwent breast conservation surgery while seven patients underwent modified radical mastectomy in view of positive nodal status.

In our series, neoadjuvant chemotherapy was given to six patients; however there was no significant response to chemotherapy. There is scant literature to support the effectiveness of chemotherapy regimens in patients with MBC. Literature indicates that MBC are associated with a worse response to standard chemotherapeutic regimens and poorer patient prognosis than typical ductal carcinomas of the breast including “triple negative” cancers. So it’s generally considered to be chemo-resistant [13]. The complex genetic and non-genetic mechanisms within the MBC that leads to phenotypically diverse subclones and intratumoural heterogeneity may be the reason for chemotherapy resistance [14]. The metaplastic cancers with a squamous epithelial component may show good response to cisplatin based chemotherapy regimens [15]. Doxorubicin and ifosfamide regimens may show good response for sarcomatoid variant of metaplastic carcinoma [16].

Adjuvant radiotherapy for MBC is also unclear. A study by Tseng WH et al., suggested that regardless of the type of operation performed (lumpectomy versus mastectomy). Adjuvant radiation improved both overall and disease-specific survival for all the patients who were undergoing treatment for MBC. Patients receiving radiotherapy demonstrated 36% and 26% decrease in death from any cause and breast-related mortality, respectively [10]. Post mastectomy radiotherapy has a more limited role. In this setting, until now, radiotherapy has not been shown to provide any advantage in patients undergoing mastectomy with tumours <5 cm

and /or <4 metastatic axillary lymph nodes. However, significant survival advantage was observed in high risk patients who were treated with mastectomy and adjuvant radiotherapy when they had tumour ≥ 5 cm and/or ≥ 4 metastatic axillary lymph nodes and chest wall invasion. This data would suggest that adjuvant radiotherapy should be included in the multimodality treatment for MBC patients undergoing mastectomy with these advanced features [10]. In our series five out of nine patients were given radiotherapy, two patients are due for radio therapy and radiotherapy not given for two patients because they died before treatment.

Hormonal therapy generally has no role in the management of patients with MBC. There is a high incidence of hormone receptor negativity as well as lower Her-2/neu overexpression in MBC. Patients with triple negative MBC have poor three year disease-free survival compared to a similar group of triple-negative IDC patients receiving identical chemotherapy regimens [17]. There have been reports that even patients with hormone positive MBC does not show any response to hormone therapy [4]. In our series of nine patients, one patient was ER and PR positive, one patient was PR and HER2 positive, rest of them were negative for hormone receptors.

MBC is an extremely aggressive disease and showed poorer prognosis compared with general IDC and TN-IDC (Triple Negative Invasive Ductal Carcinoma). It has been found that better systemic treatment is required to prevent recurrence. Poor prognostic indicators for MBC include a tumour size larger than 5.0 cm, lymph node involvement and Ki-67 index $\geq 14\%$ [18].

CONCLUSION

Metaplastic breast carcinoma is a rare entity consisting of heterogeneous subgroups; and there are no standard treatment guidelines. Surgery remains the main modality of treatment. Traditional chemo- and hormonal therapies for IDC are ineffective against MBC and often associated with poorer survival. While histology specific novel chemotherapeutic strategies may offer a survival advantage; like addition of platinum based chemotherapy regimen for squamous subgroups, or high dose anthracyclin- ifosfamide regimen for sarcoma subgroup. Regardless of the type of surgery, adjuvant radiation should be considered as a part of the treatment modality for patients with MBC. The prognosis of patients

in this rare sub group remains poor.

REFERENCES

- [1] Lakhani SR., WHO Classification of Tumours of the Breast, 4th Edition (IARC, 2012).
- [2] Kiran A, Veena M, Hasan H, Ghazala M. An usual case of metaplastic breast carcinoma(sarcomatoid variant). Indian J Surg. 2003;65:377-78.
- [3] Lai HW, Tseng LM, Chang TW, Kuo YL, Hsieh CM, Chen ST, et al. The prognostic significance of metaplastic carcinoma of the breast (MCB) - a case controlled comparison study with infiltrating ductal carcinoma. Breast. 2013;22:968-73.
- [4] Rayson D, Adjei AA, Suman VJ, Wold LE Ingle JN. Metaplastic breast cancer: prognosis and response to systemic therapy. Ann Oncol. 1999;10:413-19.
- [5] Pitts WC, Rojas VA, Gaffey MJ, Rouse RV, Esteban J, Frierson HF, et al. Carcinomas with metaplasia and sarcomas of the breast. Am J Clin Pathol. 1991;95:623-32.
- [6] Al Sayed AD, El Weshi AN, Tulbah AM, Rahal MM, Ezzat AA. Metaplastic carcinoma of the breast clinical presentation, treatment results and prognostic factors. Acta Oncol. 2006;45:188-95.
- [7] Yu Ji, Choi DH, Huh SJ, Ahn SJ, Lee JS, Shin KH, et al. Unique characteristics and failure patterns of metaplastic breast cancer in contrast to invasive Ductal Carcinoma : A Retrospective Multicenter Case-Control Study (KROG 13-07). Clin Breast Cancer. 2015;15(2):e105-15.
- [8] Kurian KM, Al-Nafussi A. Sarcomatoid/metaplastic carcinoma of the breast: aclinicopathological study of 12 cases. Histopathology. 2002;40:58-64.
- [9] Chao TC, Wang CS, Chen SC, Chen MF. Metaplastic carcinomas of the breast. J Surg Oncol. 1999;71:220-25.
- [10] Tseng WH, Martinez SR. Metaplastic breast cancer: to radiate or not to radiate? Ann Surg Oncol. 2011;18:94-103.
- [11] Gultekin M, Eren G, Babacan T, Yildiz F, Altundag K, Guler N, et al. Metaplastic breast carcinoma: a heterogeneous disease. Asian Pac J Cancer Prev. 2014;15(6):2851-56.
- [12] Benson R, Madan R, Julka PK, Rath GK. Metaplastic carcinoma breast: A case series of seven patients from a tertiary care center and review of literature. GJO. 2016;21:74-76.
- [13] Nowara E, Drosik A, Samorska- Plewicka M, Nowara EM, Stanek-widera A. Metaplastic breast carcinomas- analysis of prognostic factors in a case series. Contemp Oncol(Pozn). 2014;18(2):116-19.
- [14] Shah DR, Tseng WH, Martinez SR. Treatment options for metaplastic breast cancer. ISRN Oncol. 2012;2012:706162.
- [15] Takuwa H, Ueno T, Ishiguro H, Mikami Y, Kanao S, Takada M, et al. A case of metaplastic breast cancer that showed a good response to platinum-based preoperative chemotherapy. Breast Cancer. 2014;21(4):504-07.
- [16] Hennessy BT, Giordano S, Broglio K, Duan Z, Trent J, Buchholz TA, et al. Biphasic metaplastic sarcomatoid carcinoma of the breast. Ann Oncol. 2006;17:605-13.
- [17] Bae SY, Lee SK, Koo MY, Hur SM, Choi MY, Cho DH, et al. The prognoses of metaplastic breast cancer patients compared to those of triple negative breast cancer patients. Breast Cancer Res Treat. 2011;126:471-78.
- [18] Song Y, Liu X, Zhang G, Song H, Ren Y, He X, et al. Unique clinicopathological features of metaplastic breast carcinoma compared with invasive ductal carcinoma and poor prognostic indicators. World J Surg Oncol. 2013;11:129.

PARTICULARS OF CONTRIBUTORS:

1. Junior Consultant, Department of Radiation Oncology, Mahavir Cancer Sansthan, Patna, Bihar, India.
2. Postgraduate Resident, Department of Radiation Oncology, Mahavir Cancer Sansthan, Patna, Bihar, India.
3. Senior Consultant, Department of Radiation Oncology, Mahavir Cancer Sansthan, Patna, Bihar, India.
4. Postgraduate Resident, Department of Radiation Oncology, Mahavir Cancer Sansthan, Patna, Bihar, India.
5. Postgraduate Resident, Department of Radiation Oncology, Mahavir Cancer Sansthan, Patna, Bihar, India.

NAME, ADDRESS, E-MAIL ID OF THE CORRESPONDING AUTHOR:

Dr. A Muneer,
Postgraduate Resident, Department of Radiation Oncology, Mahavir Cancer Sansthan, Patna-801505, Bihar, India.
E-mail: muneerkhalam@hotmail.com

FINANCIAL OR OTHER COMPETING INTERESTS: None.

Date of Submission: **Mar 05, 2017**
Date of Peer Review: **Apr 25, 2017**
Date of Acceptance: **Jun 13, 2017**
Date of Publishing: **Aug 01, 2017**